

## Cranium eroding sweat gland carcinoma: a case report

Mehmet Arslan, Ahmet N. Karadeniz, Görkem Aksu, Murat Güveli

*Istanbul University, Institute of Oncology, Istanbul, Turkey*

---

**Background.** Sweat gland carcinomas are rare tumors. Eccrine sweat gland carcinomas are also very rare, with only about 200 cases reported in the world literature and only one of them was eroding the cranium. Treatment modalities of these carcinomas are not well known.

**Case report.** Our patient was 47 years old female. Since 1989, she was operated on six times because of the tumour relapses. After each operation, the pathological results were: sweat gland adenoma, sweat gland tumour, cylindroma, turban tumour, malign cylindroma. That was her seventh relapse. On examination, a lesion of the size 10 x 6 cm was observed in the left parietal region. Computed tomography showed the lesion had the size of 11 x 5 cm, and was destroying the tabula externa, diploic region and tabula. The tumour was invading the dura and causing periost reaction. Surgery and postoperative radiotherapy treatment was planned because of malign transformation and risk of recurrence.

**Conclusions.** Only one case with cranium erosion was reported in literature. In our case, also intracranial extension of the tumor was observed.

*Key words:* sweat gland neoplasms; parietal bone; neoplasms invasiveness

---

### Introduction

Little is known about these rare sweat gland carcinomas and their treatment modalities. We reviewed the literature on sweat gland carcinomas to elucidate the nature of these tumours and best treatment course. The mean patients' age is 57 years with equal male-to-female distribution. Tumour distribu-

tion is: lower extremities, 32.9%; upper extremities, 27.6%; trunk, 11.9%; head, 26.3%; neck, 1.3%. Metastasis sites are: lymph nodes, 30.2%; viscera, 22%. Malignant sweat gland carcinomas have a propensity for local and regional lymph node recurrence.<sup>1</sup> The roles of lymph node dissection, radiation, and chemotherapy were reviewed.

Apocrine gland carcinoma is a rare sweat gland neoplasm with distinctive cytological appearance. Although the region of the axilla remains the most common site for these tumours, apocrine gland carcinoma of the anogenital region, eyelid, ear, chest, wrist, lip, foot, toe, and finger have been reported. Classically, these slow-growing lesions present as painless, colourless or reddish, firm or

Received 24 March 2004

Accepted 14 May 2004

Correspondence to: Prof. Mehmet Arslan, MD, Institute of Oncology, Istanbul University, Çapa, 34390, Istanbul, Turkey; Phone: +90 532 686 4659; E-mail: marslan19@yahoo.com

cystic nodules. More than half of the reported patients with apocrine carcinoma had lymph node metastases at the time of diagnosis. Wide local excision is standard therapy for these lesions. A therapeutic lymph node dissection is indicated if lymph node metastases are confirmed. It may be effective in the setting of a large or highly aggressive tumour with narrow surgical margins. As apocrine gland carcinoma responds poorly to chemotherapy, adjuvant radiotherapy may be applied in advanced, local, or regional diseases.<sup>2</sup>

Malignant eccrine sweat gland tumours are rare and usually develop from pre-existing eccrine appendage tumour of lesser maturity.<sup>3-6</sup> Clinical features of these tumours are non-specific, and final diagnosis is always based on histology. The tumours are usually located on the head, neck, or extremities and manifest as slow-growing nodules or infiltrated plaques. These tumours are rare, with only about 200 cases reported in the world literature.<sup>7</sup> A review of the literature reveals only 25 published reports of malignancies arising from eccrine spiradenoma. These tumours have a metastasis rate of >50 per cent in reported cases with high mortality rates as a result.<sup>3</sup> The case that is reported by Ritter *et al* is the only porocarcinoma eroding the cranium. A review of the literature failed to reveal any other such case.<sup>4</sup>

Dermal eccrine cylindroma or turban tumour is a rare benign tumours of the eccrine sweat glands. Despite its histological benign behaviour, the disease process is distressing for the patients and cylindromas rarely progress to cylindrocarcinoma.<sup>8</sup>

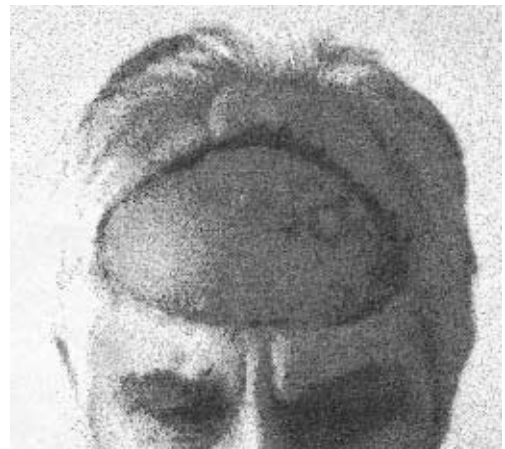### Case report

Our case is 47 years old women patient. She first visited the health care centre in 1989 for a solitary, colourless and painless lesion that she had on the scalp for a long time. On ex-

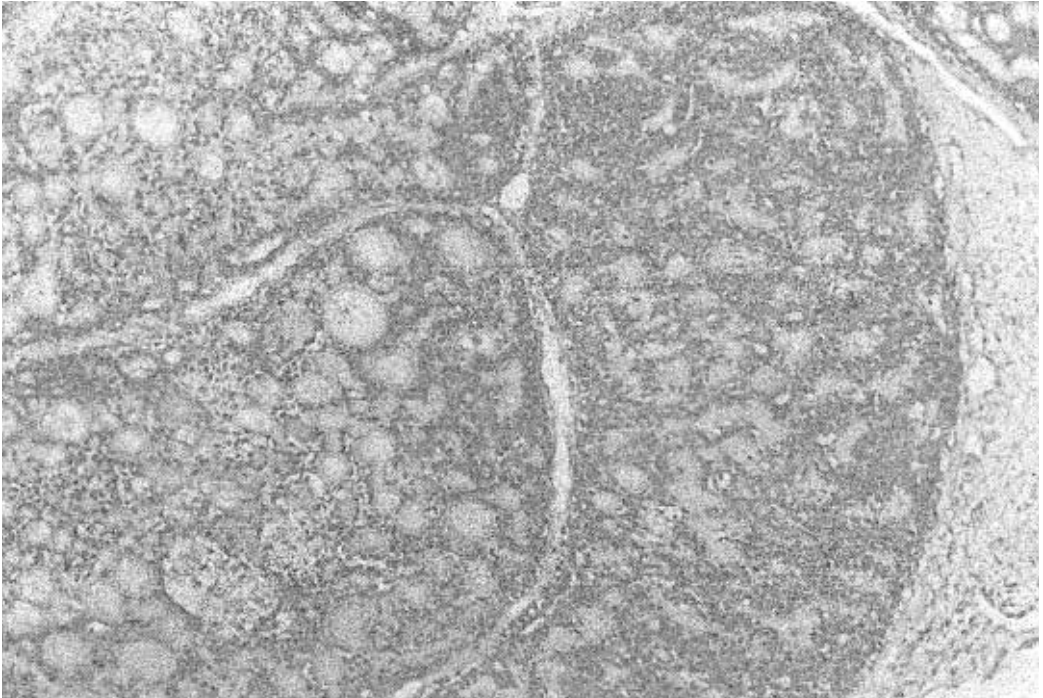
amination, colourless and painless 2 cm solid scalp lesion was palpated. The lesion was excised and not examined pathologically at that time. For about two years later, the lesion relapsed. It was excised and diagnosed pathologically as sweat gland adenoma. Adjuvant therapy was not needed. For about two years later, the lesion relapsed again. It was excised thirdly and diagnosed pathologically as sweat gland tumour. For about two years later, the lesion relapsed thirdly; this time, it was reddish. It was excised fourthly and diagnosed pathologically as sweat gland cylindroma. For about one year later, the lesion relapsed multifocally. The largest lesion was 4 cm long, reddish and painful. Other lesions were colourless, painless and solitary. The lesion was excised again and diagnosed as turban tumour. Adjuvant therapy was not needed.

Short time later, the lesion relapsed multifocally again. Dimensions of the lesions were up to 5 x 6 cm (Figure 1). The excision of the lesions, increasing in number and diameter and changing physically each time, was performed again. Pathologically, it was diagnosed as cylindroma with malign features (Figure 2).

On physical examination of the patient with recurrence referred to our clinic, a mass of the size 10 x 6 cm was found on the left



**Figure 1.** General appearance of the lesion (5x6cm).



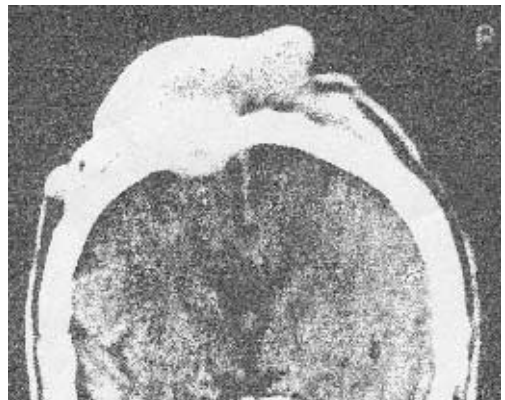**Figure 2.** Pathological appearance of the lesion (H&E, X100).

parietal region of the scalp. With cranial direct roentgen and computed tomography, a mass, measuring 11 x 5 cm, was destructing tabula, tabula externa, and diploic region, invading the dura and causing periost reaction was identified (Figure 3). Surgery and postoperative radiotherapy with surgical consultation was planned because of malign transformation and risk of recurrence.

### Discussion

Dermal eccrine cylindroma or turban tumour is a rare benign tumour of the eccrine sweat glands.<sup>9,10</sup> Women are affected 4 times more frequently than men. About 10% of all cylindromas are hereditary, transmitted autosomally dominantly and with variable penetrance. Papules, nodules, and tumours occur mainly on the scalp, but they may be found on the face and upper part of the trunk. If

nodules of cylindromas cover the entire scalp and are heaped up, they resemble a turban. Despite its histological benign behaviour, the disease process is distressing for the patients.<sup>8</sup> Cylindromas rarely progress to cylindrocarcinoma.<sup>11-13</sup> Most of these cases of cylindrocarcinomas have developed from



**Figure 3.** Radiological appearance of the lesion invading the cranium (CT).

long persisting tumours of cylindroma. Histologically, the tumours are similar to cylindromas, but they are marked by large numbers of mitotic figures and atypical mitoses. Cylindrocarcinomas are aggressive, with metastases to lymph nodes, bone, and visceral organs.<sup>6</sup> In our case, despite its histological benign features, the disease relapsed seven times and increased in dimension and number. Thus, despite its benign pathology, it was distressing for the patient. Some of them become malignant. Last pathological report of our case was cylindroma with malign features; so, it changed to a malign form from a long persisting cylindroma. A review of the literature reveals only 25 published reports of malignancy arising from eccrine spiradenoma.

These tumours are rare tumours, with only about 200 cases reported in the world literature.<sup>7</sup> The case that was reported by Ritter *et al* is the only porocarcinoma eroding the cranium. A review of the literature failed to reveal any other such case.<sup>4</sup> Our case with cranial erosion, dural invasion, and intracranial extension is the first scalp eccrine sweat gland tumour, cylindroma. Multiple resections were required for local control and, finally, the lesion changed to a growth with malign histology.

Wide local excision is standard therapy for these lesions. A therapeutic lymph node dissection is indicated if lymph node metastases are confirmed, and it may be efficient in the setting of a large or highly aggressive tumour with narrow surgical margins. As sweat gland carcinoma responds poorly to chemotherapy, adjuvant radiotherapy may be used in advanced local or regional diseases.<sup>2</sup> The treatment plan for our patient comprised wide local excision and postoperative radiotherapy because of malign transformation and risk of recurrence. The tumour invaded the dura and extended intracranially. Adjuvant treatment such as chemotherapy and craniospinal irradiation may be applied. But these tumours re-

spond poorly to chemotherapy and there is no experience of craniospinal irradiation.

## Conclusions

The reported case with cranial erosion, dural invasion, and intracranial extension is the first scalp eccrine sweat gland tumour, cylindroma. Cylindromas rarely progress to cylindrocarcinoma. Most of these cases of cylindrocarcinomas have developed from long persisting tumours of cylindroma. In our case, it also changed to malign cylindroma. Wide local excision is standard therapy for these lesions. Multiple resections may be required in order to obtain local control even if the lesion is benign. Therapeutic lymph node dissection and adjuvant radiotherapy may be used in advanced local or regional diseases.

## References

1. Asley I, Smith-Reed M; Chernys A. Sweat gland carcinoma. *Dermatol Surg* 1997; **23(2)**: 129-33.
2. Chamberlain RS, Huber K, White JC, Travaglino-Parda R. Apocrine gland carcinoma of the axilla. *Am J Clin Oncol* 1999; **22(2)**: 131-5.
3. Beekly AC, Brown TA, Porter C. Malignant eccrine spiradenoma. *Am Surg* 1999; **65(3)**: 236-40.
4. Ritter AM, Graham RS, Amaker B, Broaddus WC, Young HF. Intracranial extension of an eccrine porocarcinoma. *J Neurosurg* 1999; **90(1)**: 138-40.
5. Tay JS, Tapen EM, Solari PG. Malignant eccrine spiradenoma. *Am J Clin Oncol* 1997; **20(6)**: 552-7.
6. Shafer WF, Hine MK, Levy BM, editors. *A textbook of oral pathology*. Philadelphia: WB Saunders; 1983. p. 20.
7. Safai B, Brash DE. Tumors of eccrine glands. In: Vincent T, DeVita, editors. *Cancer*. Philadelphia: Lippincott-Raven; 1997. p. 40.
8. Irwin LR, Bainbridge LC, Reid CA, Piggot TA, Brown HG. Dermal eccrine cylindroma (turban tumour). *Br J Plast Surg* 1990; **43(6)**: 702-5.

9. Cotton DW, Braye SG. Dermal cylidromas originate from the eccrine sweat gland. *Br J Dermatol* 1984; **111**: 53-61.
10. Goette DK, McConnell MA, Fowler VR. Cylindroma and eccrine spiradenoma coexistent in the same lesion. *Arch Dermatol* 1982; **118**: 273-4.
11. Urbanski SJ, From L, Abramowicz A, Joaquin A, Luk SC. Metamorphosis of dermal cylindroma: possible relation to malignant transformation. Case report of cutaneous cylindroma with direct intracranial invasion. *J Am Acad Dermatol* 1985; **12**: 188-95.
12. Lyon JB, rouillard LM. Malignant degeneration of turban tumour of scalp. *Trans St Johns Hosp Dermatol Soc* 1961; **46**: 74-7.
13. Bondeson L. Malignant dermal eccrine cylindroma. *Acta Derm Venereol* 1979; **59**: 92-4.