

# The role of sentinel lymph node detection in vulvar carcinoma and the experiences at the Institute of Oncology Ljubljana

Aleš Vakselj and Sonja Bebar

Department of Gynecological Oncology, Institute of Oncology Ljubljana, Ljubljana, Slovenia

**Background.** Sentinel node biopsy is a promising diagnostic staging procedure for vulvar carcinoma and it decreases postoperative morbidity. However, it has not been yet approved as a standard procedure.

**Patients and methods.** From March 2003 to the end of 2006, 35 patients were treated for vulvar carcinoma with the technique of sentinel lymph node dissection. Mean age of the patient was 65.8 years (range 36-88 years). There had 32 patients squamous cell carcinoma, one malignant melanoma, one basal cell carcinoma, and one adeno-squamous cell carcinoma. Before surgery, sentinel node biopsy was made with performing  $^{99m}\text{Tc}$  static and dynamic lymphoscintigraphy and with intradermal injection of methylene blue dye.

**Results.** With this method we haven't found metastases in 25 patients (71.4%). In 3 cases, we failed and found groin recurrence after 12, 24 and 26 months, respectively. In the first, the reason was probably lack of experience, in the second case, we couldn't detect the second active node seen on the lymphographic scan, and in the third case, the reason was a prior surgical procedure and a scar in the groin region.

In the group of SNB negative 22 patients were alive at the end of the year 2007 with no evidence of disease, one died after 45 months (groin recurrence), another one died of other causes. For one patient there is no current data. Patient with melanoma malignum is alive with liver metastases.

**Conclusions.** In order to recognize the value of the obtained knowledge about the new treatment method and to confirm the efficiency or inefficiency of this method, further multicenter research studies need to be performed on larger randomized groups of patients.

*Key words:* vulvar neoplasms; lymphatic metastasis-radionuclide imaging; sentinel lymph node biopsy

## Introduction

Vulvar carcinoma accounts for 4% of all gynecological cancers. The most frequent cancer type (90%) is squamous cell carcinoma;

others are rather rare. The mean age of patients at the diagnosis of vulvar carcinoma is 70 years.

The progression of the vulvar squamous cell carcinoma usually takes one of the following three courses: most often, it infiltrates into inguinofemoral lymph nodes, while the other two, hematogenous or direct metastasizing, are not so frequent.

The survival of patients with the diseases at all stages and the depth invasion

Received 3 December 2007

Accepted 14 December 2007

Correspondence to: Aleš Vakselj, MD, Department of Gynecological Oncology; Institute of Oncology Ljubljana, Slovenia; Phone: +386 1 5879 620; Fax: +386 1 5879 400; E-mail: avakselj@onko-i.si

of >1 mm, treated with radical vulvectomy and inguinofemoral lymphadenectomy, is nearly 70%.

The most significant prognostic factor is the number of metastatic inguinofemoral lymph nodes.

Despite fairly high survival of patients, short- or long-term morbidities associated with the above mentioned radical surgical technique are worryingly high. These morbidities, which considerably prolong hospitalization, are infections, lymphocysts, scar dehiscence and lymphatic edema of the lower limbs.

A standard treatment modality applied in early stages of vulvar carcinoma (T1, tumor <2cm; T2, tumor >2cm), not accompanied by palpable inguinal lymph nodes enlargement, is extensive local excision of the tumour with the safety margin of 1 cm and uni- or bilateral inguinofemoral lymphadenectomy, both performed in two separate incisions. Postoperative radiotherapy is indicated if more than one node is metastatic.

In early stages of the disease, metastatic involvement of inguinofemoral lymph nodes is observed in 20-30% of patients. The rest of the patients (70%) do not benefit significantly from surgical intervention; however, a considerable increase in morbidity rates has been observed. Since the introduction of the technique with two separate incision sites, the number of complications decreased, though lymphoedema, lymphocysts or scar dehiscence are still fairly frequent.

No reliable method for determining the inguinofemoral nodes status has been so far developed. Palpation can detect just about 25% of all metastatic nodes. The results of ultrasound (US) and positron emission tomography (PET) examinations are unsatisfactory, whereas the potential of the computer tomography (CT) examination in the search of metastatic nodes has not been

extensively described in the literature. The sensitivity of magnetic resonance imaging (MRI) was assessed to range between 40-50% and the specificity, between 90-100%. Among the most promising methods for detecting metastases in the regional nodes is US-guided fine-needle biopsy though, admittedly, it requires highly skilled operators in order to yield success and efficiency.<sup>1</sup>

On account of so sparse non-invasive techniques for determining the inguinofemoral nodes status, of non-involved nodes in the majority of patients with a low stage vulvar carcinoma and on account of frequent morbidity following lymphadenectomy, there was an urgent need to develop a minimally invasive surgical technique for diagnosing vulvar carcinoma, i.e. sentinel lymph node detection (SLND).

### *Sentinel lymph node – what is it?*

The sentinel lymph node is the first node in the lymphatic basin into which the lymph from the primary tumour is drained; histological examination of the sentinel lymph node is hypothetically representative for the rest of the nodes in the region. A histologically negative sentinel lymph node should be indicative for the absence of the metastases in all other non-sentinel nodes.<sup>2</sup>

### *Sentinel lymph node biopsy – when and how?*

The sentinel lymph node biopsy should be performed in the patients in whom

- vulvar carcinoma with the in-depth invasion of more than 1 mm was confirmed histologically,
- injection of the necessary substances into the tumour surrounding is possible, and
- no enlarged or fixed lymph nodes were detected in the inguinal region.

Before the operation, the patient should be fully informed of the details of the examination, to what purpose the results of the examination would serve, how the examination would affect further treatment, and that the treatment is only experimental. The treatment can be started only after obtaining the informed consent signed by the patient.

The sentinel lymph node should always be marked in two ways, i.e. with  $^{99m}\text{Tc}$  (Technetium) labeled nanocolloid and with blue dye; this is the most reliable marking method assuring that the node will absolutely be found later. According to the literature, the injection of blue dye alone detects the sentinel node only in 56-88% of cases.<sup>3</sup>

Given that the injection of nanocolloid is a painful procedure, it is recommended that an anaesthetic gel is applied to vulva before the injection;<sup>4</sup> at our Institute, we usually apply local anaesthetic cream EMLA.

Colloid is then injected with a fine needle at four separate injection sites alongside the peripheral tumour margin. Care should be taken that nanocolloid does not get spilled over the vulva or inguinal area because tiny radioactive particles detected by scintigraphy may compromise the image interpretation.

The patient is immediately transported to the isotope treatment unit where first a dynamic and then a static lymphoscintigraphies are performed by gamma camera. The first active and persistent spot found by this technique is sentinel node; its location is marked on the skin. Sometimes, two highly active sites may be found; in these cases, both are marked on the skin.<sup>1</sup>

The blue dye is applied immediately before surgery. It is injected at four separate sites alongside the tumour margin. On the site marked on the skin incision, approximately 3-4 cm long, is made; the tissue is then carefully pushed aside in order to avoid severe haemorrhage that would ob-

struct the detection of the blue-dyed node. The node's activity is checked by portable gamma-ray detector. The node is then cautiously excised. If the next node is also dyed blue, it should be removed, too despite lower activity. If the carcinoma is located in the centre, the sentinel node on the other side should be removed, too. After sentinel lymph nodeectomy, the excision of tumour with a wide safety margin should be performed. Radical vulvectomy is recommended only in cases of multifocal growth of the tumour.

The nodes excised during surgery may be sent to cytology laboratory for intraoperative evaluation of the samples by imprint cytology. The frozen section technique is not advised because it destroys the excised node completely so that no further examinations are possible. However, the surgeon may finish the operation a few days later after having received the results of the imprint cytology. If the results confirm metastatic involvement in the node, inguinofemoral lymphadenectomy or postoperative irradiation of the affected area should be performed; the decision between the two options depends on health condition of each patient and on other of prognostic factors.

## Patients and methods

In 2003, in view of the data from the literature reporting a 100% negative prognostic value<sup>3</sup> we decided to apply a new method of treatment, i.e. removal of sentinel lymph nodes alone. The Department of Surgical Oncology at the Institute of Oncology Ljubljana is known to be very skilled in sentinel lymph nodes biopsies in the treatment of breast cancer and malignant melanoma [2005 – 537 biopsies (383 breast cancer, 147 melanoma malignum), 2006 – 529 biopsies (351 breast cancer, 172 melanoma malignum)]. Their experience

was most welcome also in gynaecological oncology and facilitated the introduction of these techniques also in gynaecological oncology.

From March 2003 to the end of 2006, 35 patients were treated for vulvar carcinoma with the technique of sentinel lymph node dissection. Mean age of the patient was 65.8 years (range 36-88 years). According to histology analysis results, 32 patients had squamous cell carcinoma, one malignant melanoma, one basal cell carcinoma, and one adeno-squamous cell carcinoma.

Two hours before surgery, the patients were injected intradermally with  $^{99m}\text{Tc}$  nanocolloid in four quadrants lining the outer margins of the tumour. Static and also dynamic lymphoscintigraphies (Figure 1) were then performed detecting active nodes and the locations were marked on the skin (Figure 2).

Before surgery, methylene blue dye was injected intradermally, too. The first five operations were performed under the supervision of an IAEA instructor.

During operation, sentinel nodes were detected by hand-held gamma probe. In

all cases, we first excised the lymph nodes that were dyed blue and active and then the nodes that were not dyed, but still active. After the removal of the nodes, the tumour on the vulva was excised. In all surgical interventions, a conservative approach was followed, i.e. only the tumour with a wide safety margin was removed and not the entire vulva. In 19 cases, unilateral nodectomy was performed, whereas in 16 cases, nodectomy was bilateral.

## Results

### *Metastatic nodes*

Sentinel node biopsies were positive (SNB+) in 10 out of 35 patients (28.6%), which is consistent with the data from the literature. In 4 patients, the sentinel nodes were identified bilaterally, and in two cases, the nodes were metastatic on both sides. In all patients, postoperative care was normal, without serious complications.

In one patient, a cluster of clinically metastatic nodes was detected behind the positive sentinel node. Therefore, all nodes

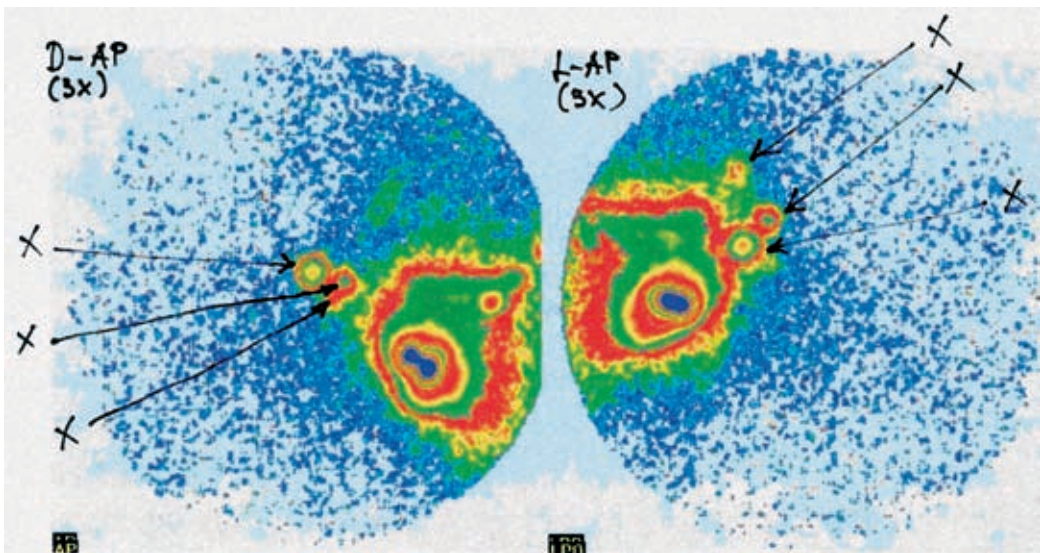


Figure 1. Vulvar static lymphoscintigraphies with  $^{99m}\text{Tc}$  nanocolloid.

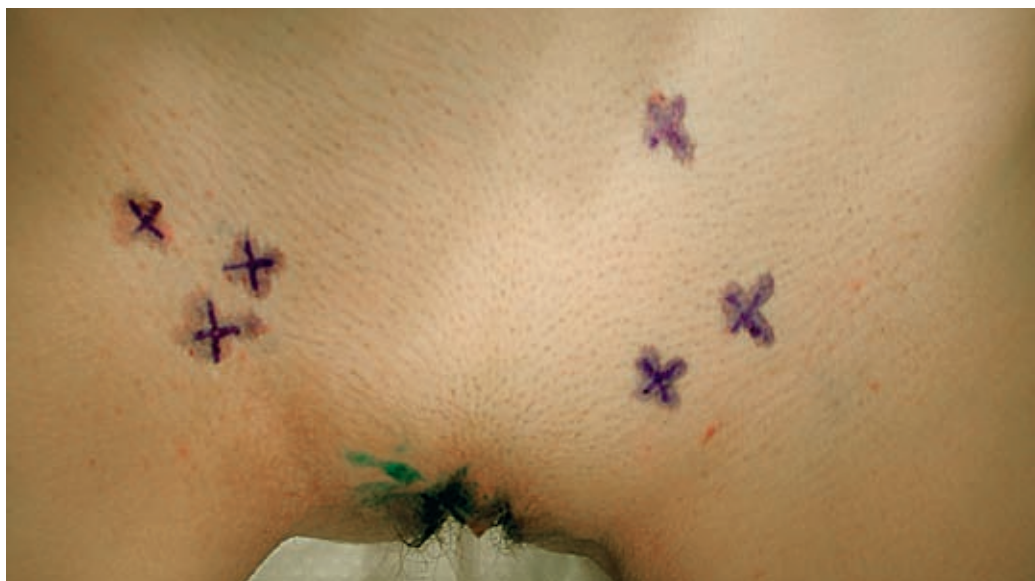

Figure 2. Active nodes were marked on the skin.

down to the femoral canal were removed. The patient underwent also CT examination which detected that deeply seated pelvic lymph nodes were also metastatic.

In 3 patients, reoperation (inguinofemoral dissection) was required, and 9 were treated with postoperative irradiation. Six patients died of the disease spread; in 4

patients, the disease progressed into the inguinal area; in four patients, no evidence of disease was found. In one patient, local recurrence was observed 43 months after the completed therapy. Local excision was performed and the patient was also irradiated. The patient was without evidence of disease after 55 months (Table 1).

Table 1. Positive sentinel node biopsies (SNB+)

PT	Histology	SNB	Treatment	Age	Status (nov 2007)	Time (months)
1	Squamous, G1	+ L	Reoperation + irradiation	57	NED	55
2	Squamous, G2	+ L, + R	+ irradiation	69	DOD	42
3	Squamous, G3	+ R	+ irradiation	58	DOD	10
4	Squamous, G3	+ L	+ irradiation	59	DOD	?
5	Squamous, G2	- R, + L	+ irradiation	63	NED	36
6	Squamous, G2	+R	Reoperation + irradiation	65	DOD	3
7	Squamous	+ R	+ irradiation	71	DOD	18
8	Squamous, G2	+ R, + L	+ irradiation	76	DOD	10
9	Squamous	+ R, - L	Reop. (rad. limfadenectomy)	67	NED	25
10	Adenosquamous	+ L	+ irradiation	73	NED	11

**Table 2.** Negative sentinel node biopsies (SNB-)

PT	FIGO Stage	Histology	SNB		Age	STATUS (nov 2007)	Time (months)
1	IB	Squamous, G1	- L, - R		61	NED	34
2	II	Squamous, G2	- R		78	NED	51
3	II	Squamous, G1	- L, - R	Groin recurrence after 24 months - reoperation	80	DOD	49
4	I	Squamous	- L, - R		70	NED	52
5	I	Squamous, G1	- R		70	NED	46
6	I B	Squamous	- L		63	NED	46
7	I	Baseo- Squamous	- L, - R	Groin recurrence after 26 months - reoperation	67	NED	43
8	I	Planocelular, G3	- L, - R		46	NED	45
9	I	Squamous, G1	- L		49	NED	46
10	I B	Squamous, G1	- R		76	NED	35
11	I B	Microinvasive, (1,6mm)	- L, - R		72	NED	38
12	II	Squamous, G1	- R		87	DOC	
13	I B	Squamous, G1	- R	Groin recurrence (scar) after 12 months, reoperation	80	NED	36
14	II	Bazeocelular	- R		83	NED	31
15	II	Squamous, G2	- R, - L		88	NED	18
16	I	Squamous, G1	- L		36	NED	33
17	II	Squamous, G1	- R, - L		48	NED	35
18	I B	Squamous, G1	- R, - L		53	NED	28
19		Melanoma malignum	- R, - L	reoperation + irradiation	47	AWD	33
20	I	Squamous, G1	- R		75	NED	25
21	I	Squamous, G1	- R, - L		50	NED	18
22	I	Squamous, G2	- R		79	NED	2
23	I	Squamous, G1	- R		58	NED	14
24	I	Squamous	- R		63	NED	18
25	I	Squamous, G1	- R, - L		66	NED	15

L = left; R = right

### *Nodes without metastatic involvement*

Sentinel node biopsies were negative (SNB-) in 25 out of 35 patients (71.4%). Postoperative complications were not observed; the patients were therefore dis-

missed from the hospital 2 or 3 days after surgery. In three patients, recurrence in the inguinal region was detected 12, 24 and 26 months after the completed primary treatment, respectively. In one patient, the cause

of the recurrence could be assigned to the inexperience of the surgeon; in the second, the node, next to the sentinel node, which was active, was not identified; and in the third patient, the active node did not show up because of a scar of an earlier operation in the inguinal region.

By the end of 2007, 22 patients are alive, 21 of them with no evidence of disease (NED), one died with groin recurrence and lung metastases after 49 months, one died of other causes, and patient with melanoma malignum is alive with the disease (liver metastases) (Table 2). One patient (N<sup>o</sup> 22) was lost in the follow up.

## Discussion

The first who, as early as 1991, assumed that the superficial inguinal lymph nodes in vulvar carcinoma serve as sentinel nodes for the deep-lying ones was DiSaia et al. The first study dealing with this subject was published by Levenback et al in 1994. He and his team detected the sentinel nodes by using blue dye and verified the reliability of the method by complete inguinofemoral lymphadenectomy performed later on.

Three years later, deCesare published the results of his study made on intraoperative sentinel node detection by using a gamma-ray detector. Both methods were then merged by Hullu who used lymphoscintigraphy to mark the nodes preoperatively and the blue dye to detect them intraoperatively.<sup>1</sup>

Both sentinel lymph node marking techniques are suitable; however, the best results are usually obtained by the combination of both. From the reported data, it is evident that the methods applying the combination of both yield a 100% success, whereas blue dye applied alone is successful in only 56-88% of cases.<sup>5</sup>

## Conclusions

Sentinel node biopsy is a promising diagnostic tool in the evaluation of vulvar carcinoma and of node status as well as of disease stage. Due to low incidence of squamous cell carcinoma of the vulva, the experiences in the above treatment of this cancer are not so rich and the data in the literature are scarce; therefore, this treatment modality is applied more or less as an experimental method as it has not been yet approved as a standard method. In order to recognize the value of the obtained knowledge about the new treatment method and to confirm the efficiency or inefficiency of this method, further multicentre research studies need to be performed on larger randomized groups of patients.

## References

1. de Hullu JA, van der Zee AG. Sentinel node techniques in cancer of the vulva. *Curr Womens Health Rep* 2003; 3: 19-26.
2. Sliutz G, Reinthaller A, Lantzsch T, Mende T, Sinzinger H, Kainz C, et al. Lymphatic mapping of sentinel nodes in early vulvar cancer. *Gynecol Oncol* 2002; 84: 449-52.
3. Puig-Tintore LM, Ordi J, Vidal-Sicart S, Lejárcegui JA, Torné A, Pahisa J, et al. Further data on the usefulness of sentinel node identification and ultrastaging in vulvar squamous cell carcinoma. *Gynecol Oncol* 2003; 88: 29-34.
4. De Cicco C, Sideri M, Bartolomei M. Sentinel node biopsy in early vulvar cancer. *Br J Cancer* 2000; 82: 295-9.
5. De Hullu JA, Hollema H, Piers DA, Verheijen RH, van Diest PJ, Mourits MJ, et al. Sentinel lymph node procedure is highly accurate in squamous cell carcinoma of the vulva. *J Clin Oncol* 2000; 18: 2811-6.
6. De Hullu JA, Van der Avoort IA, Oonk MH, van der Zee AG. Management of vulvar cancers. *Eur J Surg Oncol* 2006; 32: 825-31